

Overview of Facial Asymmetry

Dr. Hussain Alabduljabbar¹, Dr. Samar AlSaeed², Dr. Tamer Aljamaan³

¹Consultant Orthodontist, King Abdulaziz Naval base Hospital, Jubail, KSA

²Consultant Orthodontist, King Abdulaziz Naval Base Hospital, Jubail, KSA

³Consultant Prosthodontist, King Abdulaziz Naval Base Hospital, Jubail, KSA

Abstract: The orthodontic correction of facial asymmetries is often considered a difficult and challenging process, primarily because of misdiagnosis and poorly planned treatment mechanics. A careful differential diagnosis together with a thorough treatment plan can ensure successful treatment outcomes in the management of these malocclusions. In this article, key elements of differential diagnosis and treatment planning are reviewed.

Keywords: orthodontic correction, facial asymmetries, poorly planned treatment mechanics.

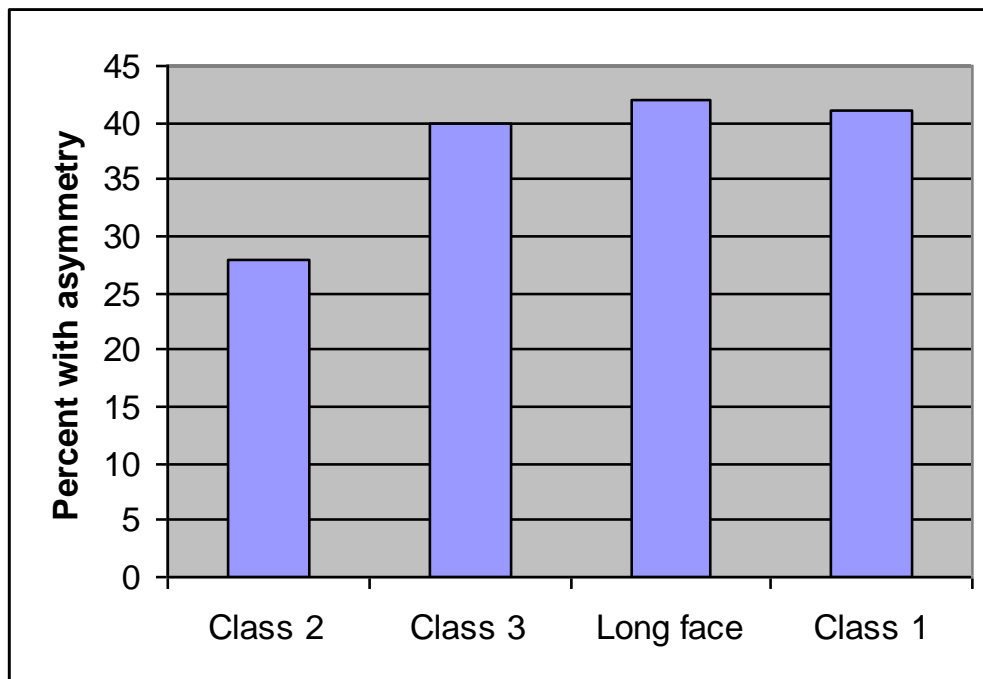1. INTRODUCTION

Asymmetric malocclusions are common orthodontic problems that are challenging to correct successfully. Often patients are not aware of a major asymmetry, when accompanied by other skeletal deviations, It takes on a greater significance. Patient will see it every time looking in a mirror in contrast to profile problems. Optimal treatment outcomes are primarily based on early recognition of the asymmetric malocclusion and proper diagnosis and treatment planning. The orthodontic management of a malocclusion with some degree of asymmetry is usually challenging because it is necessary to use asymmetric mechanics in the right and left quadrants of the dental arch to achieve acceptable correction. Significant undesirable side effects of the mechanics can occur in the correction. Also, if the nature of the asymmetry has been misdiagnosed, the prognosis for successful treatment is greatly compromised. The orthodontic correction of dental asymmetries is often considered a It is important to diagnose the underlying cause of occlusal asymmetry so that an appropriate treatment plan can be efficiency implemented. Asymmetric malocclusions may be caused by an underlying skeletal asymmetry, mandibular shifts from initial tooth contact to maximum intercuspal position, or dental asymmetry of purely dental origin.

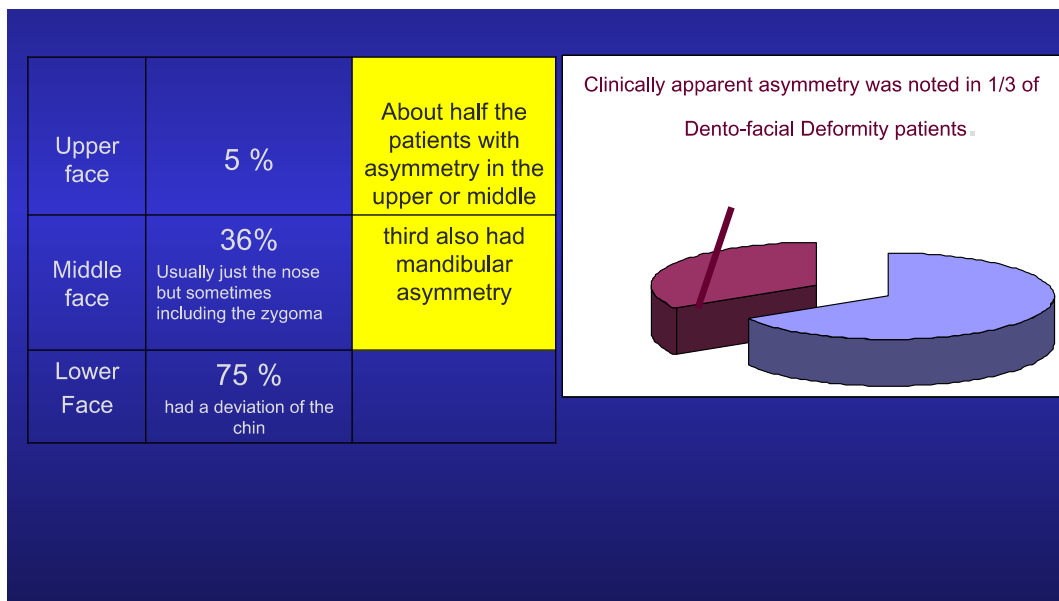
Skeletal asymmetries may be the result of congenital anomalies, such as hemifacialmicrosomia. Affected individuals show underdevelopment of the condylar-ramal complex on the involved side, along with ear malformations, Hemifacialmicrosomia has a variety of clinical presentations with varying degrees of deformation of the mandible on the affected side. The type and timing of treatment depends on the degree of deformation and the philosophy of treatment. Early treatment may involve the use of an asymmetric functional activator, distraction osteogenesis, or placement of a costochondral rib graft. Definitive orthognathic surgery may be required. Treatment goals include optimizing facial growth and minimizing secondary asymmetric development of the maxilla and canting of the occlusal plane. Condylar fracture during childhood has been associated with growth arrest and subsequent asymmetry. As normal facial growth continues, the mandible may progressively deviate toward the affected side or, in some cases, compensatory overgrowth of the fracture site may occur, producing an asymmetry with mandibular deviation away from the affected side.

When the chin deviated it was overwhelmingly to the LEFT for all subgroups(Except in the Long face group- Equal distribution of R & L asymmetry.)

For all those with asymmetric mandibular growth, the normal tendency- for a larger RIGHT side of the face is accentuated.



Relationship between the type of malocclusion and the prevalence of asymmetry



Prevalence of asymmetry in upper, middle, and lower face

Terminology:

- Symmetry- Balance
- Asymmetry- Obvious imbalance
- Bilateral body symmetry theoretical rather than practical
- Dentoalveolar structures show more symmetry than other parts of the orofacial region Vig& Hewitt because of their capacity to compensate
- More a problem with the basal bones and the skull rather than the dento-alveolar structures
- Most faces have a degree of asymmetry- perfect symmetry rare.

- Most cases R side of face larger than L (Proffit 2003) studies differ depending on population
- In jaw function Mild asymmetries in the dental arches are common causing no difficulty Patient Perception
- Often patients are not aware of a major asymmetry
- When accompanied by other skeletal deviations, asymmetry not chief complaint. Proffit
- But if it is their major concern it takes on a greater significance.-see it every time look in mirror in contrast to profile problems
- In Class I patients with asymmetry as the only skeletal problem -42% focused on the asymmetry as the chief complaint and -58% focused on their teeth (Servert&Proffit 1997)

2. ETIOLOGY

Genetic or congenital malformations:

Normal variation:

- asymmetric skeletal development Excessive variation

Syndromes:

Craniofacial microsomia,

Retinoic acid and thalidomide teratology,

Clefting syndromes,

Craniofacial synostoses,

Multiple neurofibromatosis.

Developmental Environmental:

- Trauma- condylar fracture-functional ankylosis
- Habits- sucking,
- asymmetrical chewing due to caries extractions and trauma
- Intrauterine pressure

Pathology:

Tumours: e.g.osteochondroma,neurofibroma,infection,

- Rheumatoid Arthritis in childhood
- Osteomyelitis

Functional:

Mandibular displacement

- e.g. premature contacts, constricted Maxilla

Local Factors

- Retained/missing teeth

Clinically apparent asymmetry was noted in 1/3 of Dento-facial Deformity patients:

Upper face 5 %

About half the patients with asymmetry in the upper or middle Clinically apparent asymmetry was noted in 1/3 of Dento-facial Deformity patients.

Middle face 36%

Usually just the nose but sometimes including the zygoma third also had mandibular asymmetry

Lower Face 75 %

had a deviation of the chin

Classifications of asymmetry

Bishara 1994 –Classified according to the structures involved

- Dental asymmetry
- Skeletal asymmetry Functional asymmetry
- Muscular asymmetry of head and neck
- Combination of these factors

Lundstrom 1961

- Quantitative
e.g. Differences in the number of teeth Cleft palate
- Qualitative
e.g. Differences in the size of teeth

Differences in the location of teeth in the arches Differences in the position of arches in the head

Obwegeser 1986

classification of Skeletal asymmetries Journal of Maxillofacial Surgery

- hemimandibular elongation
- hemimandibular hyperplasia.

Clinical examination

Note relevant Medical Dental History

e.g. Syndromes, trauma, TMD

Overall assessment of development Detailed Facial examination in 3 planes

- Vertical
- Transverse
- AP

NHP(Natural Head Position)

View from the front, behind, submentovertex.

- Compare bilateral structures
- Forehead
- Orbital
- Zygomatic
- External ear position
- Look for deviation of the Nose, dorsum, tip philtrum. chin point
- Position and contour of the chin, inferior border, angle

- Relate Cant maxillary plane to inter-pupillary plane
- Compare right and left facial heights

Functional evaluation

- TMJ
- Evaluate Dental midline- mouth open, Centric relation, initial contact, & MIP
- Mandibular excursions, displacements on closure
- Maximum inter-incisal Mouth opening

Soft tissue in repose

- Look for bilateral asymmetry

Dental

View from above establish facial midline and retract upper lip to reveal dental centerline

& to the lower dental CL

- Compare right & left crowding
- Assess mesio-distal angulations
- Vertical- open bites
- Transverse- XB, BL tooth position and inclinations,
- AP BSR- compare R/L
- Local factors missing teeth etc.

Diagnostic records

Photographs

Frontal, lateral, ¾ views, intra-oral -document initial condition

Further Imaging:

Tomographs

MRI-degenerative and adaptive osteocartilagenous

-help to establish problem list

Computed Tomography (CT) images

-treatment plan

-evaluation of treatment results,

-baseline for progressive cases

Study models

-3d view of dental relationships

-examine each dental arch and quadrant

Radiographs/Cephalometric analysis

Ceph

PA Ceph,

DPT

Study models mounted on SA Articulator

The relationship of the jaws in 3 planes examine rotation of mx or md

Computerized axial tomography scan to create 3d images that can be rotated-severe cases

-Scintigraph

Models for surgical planning

- Model surgery
- Stereolithographic modelling (model of facial skeleton milled using information from CAT scan)

-Diagnosis and surgical planning craniofacial surgery

-Size plates and distraction devices

-Expensive so not for routine dento-facial patients at present-.craniofacial.

-additional information in hypertelorism, severe asymmetries of the neuro- and viscerocranium, complex cranial synostoses and large skull defect.

-"duplicates" of complex or rare dysmorphic craniofacial pathology for the purpose of creating a didactic collection

Radiographic examination

- Lateral Ceph – Limited value in diagnosing asymmetry.
- Magnification discrepancies.R/L face at different.
- Postero - anterior Projection.
- Clinician decides where to place ear rods.

prior to exposure differences from the source and screen.

- Improper head positioning can create or conceal asymmetry.
- Demonstrates if maxilla has an occlusal cant.
- Lateral Ceph taken in NHP & it is assumed ears are at same vertical level in this position.
- Use only one of ear rods when the cephalogram is taken or -The head will be tilted in a way that conceals the asymmetry.
- Compare R&L structures, located relatively equal distances from the film/ screen and RG source.
- Views- Maximum intercuspation, Mouth asymmetry
- attention to correct midsagittal plane perpendicular to the floor
- DPT –Useful survey but the way the image acquired results in magnification differences within different areas of the film so measurements not possible.
- comparison from side to side dental & bony

Structures open

- Analyzing the PA cephalometric radiograph Don't rely solely on measurements

-Landmark identification is unreliable

=Tracing error may hide small deviations

- Compare shape and size of the condylar heads
- Contour size, shape mandibular border
- Hypoplasia/hyperplasia of one side

- Compare gonial notches, gonial angles
- Compare heights of vertical rami
- Compare heights of R & L occlusal planes Compare concavities on posterior aspect of the vertical rami-Minor deviations may appear to exist that do not
- Note the relationship of the transorbital plane to the maxillary occlusal plane

Asymmetry Analysis-No technique is universal

Radiographic analysis PA Ceph assessment

Linear or angular measurements

- Grummons and Kappeyne van de Copello 1987
- Severt and proffit 1997a

Anatomic approach Harvold 1954

- Horizontal axis line through zygomatico frontal sutures
- Vertical perpendicular(midsagittal plane) bisects the base of the crista galli
- Perpendiculars from bilateral structures are constructed to this reference line
- Measure discrepancies in height and distance between structures and the midline
- Compare dental to skeletal midline Bisection approach
- Bilateral landmarks are located and bisected
- Reference line constructed through midpoints of bilateral landmarks

Triangulation approach Vig & Hewitt 1974, Hewitt 1975

Identify bilateral structures and midline

Triangles are constructed that divide the face into components The R & L triangles are compared for symmetry

Right Left Differences

- Chebib and Chamma 1981
- Peck et al 1991
- Slolnick et al 1994 Grummons et al 1994

Submento vertex assessment

- Forsvberg et al 1984
- Arnold et al 1994
- Rose et al 1994
- Invasive do not take into account soft tissue morphology

3d Techniques

- photometry
- Laser scanning (Moss et al 1991)

Digitized Facial photographs

Edler et al 2002

Timing of Treatment:**1- Preadolescent Children Asymmetry due to**

- Congenital Hemifacialmicrosomia
- Acquired -Growth deficiency 2' to trauma (condylar fracture)
- Other causes e.g. juvenile rheumatoid arthritis

Treatment:

Mild cases asymmetric functional appliances

Severe cases Early surgery

Goal of early surgery improve the chances of subsequent favorable growth.

Surgery should be growth neutral -no deleterious effects on growth.

Affected patients will need treatment as long as deviant growth pattern might continue whether or not surgery is carried out at an early age.

2-Adolescents

Excessive unilateral growth of Mandible

After adolescent growth spurt - Severe asymmetry is usually because of excessive growth:

Hemimandibular Hypertrophy/ Hemimandibular elongation

Asymmetric mandibular deficiency secondary to condylar fracture

Even if adolescent suffers a condylar fracture at this stage that restricts translation there is not enough growth remaining to cause more than moderate asymmetry. Condylar fracture managed best with a functional appliance until growth is complete or all but complete to prevent the development of maxillary as well as md asymmetry if possible followed by corrective surgery as necessary.

3-Adults

Orthognathic surgery

Dental arch form- asymmetry:

Rotation of entire arch and its supporting skeletal base.

- Asymmetric skeletal development Asymmetric positioning e.g. Asymmetric development of the cranial base can lead to asymmetries in the position of the glenoid fossa.

A fossa that is in a more anterior position relative to the other fossa may produce a rotation of the md relative to the Mx and an asymmetric occlusion even if the mx and the md are not significantly asymmetric in form class 3 on the side of the more anterior fossa.

- These asymmetries also produce midline discrepancies if not masked by other dentoalveolar compensations.
- Rotations of the maxilla relative to the cranial base can produce an asymmetric occlusal relationship, even when the glenoid fossa are symmetrically positioned.

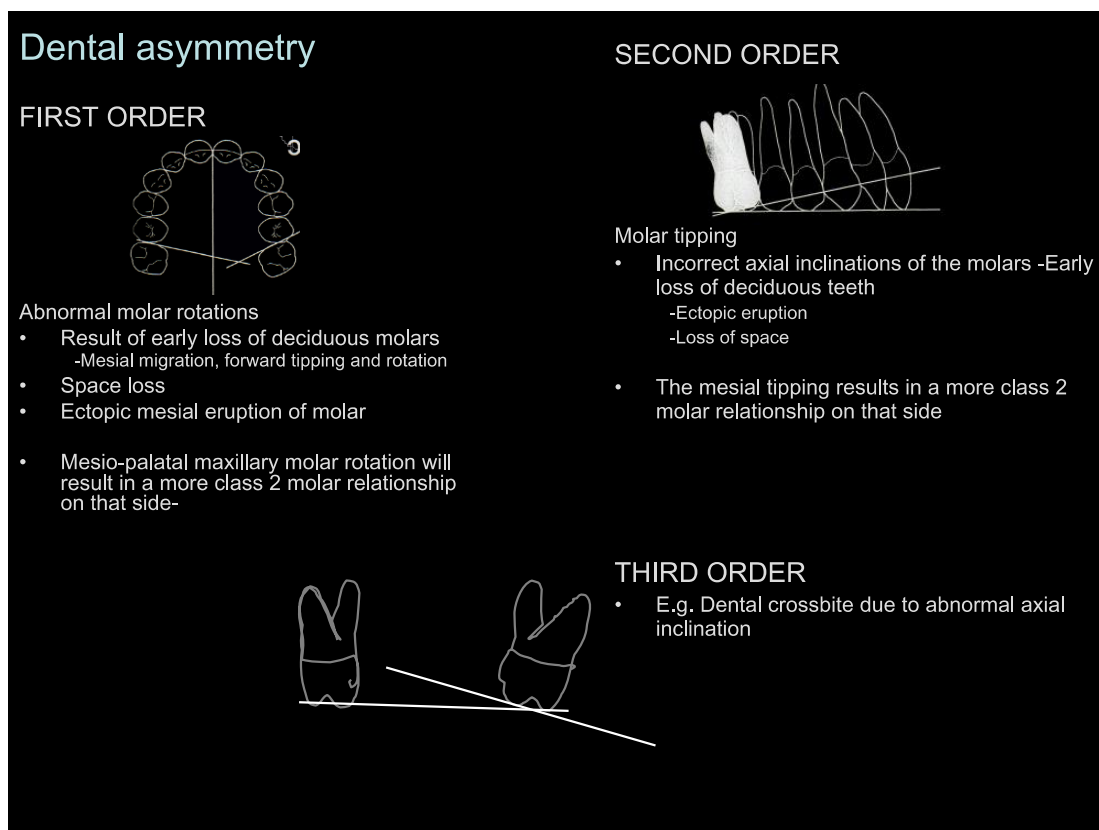
Asymmetric morphology

- Eg Differences in length of the body of the md as well as differences in height of the developing ramus.

Local factors e.g.

- crowding
- Any space loss e.g. interproximal caries, early loss of primary teeth e.g. E, -5 erupts palatally,

- Retention of primary teeth e.g. E, -5 erupts palatally
- Ectopic eruption and centreline shift
- Congenital absence of teeth
- Small teeth e.g. peg laterals
- Infraocclusion
- Impaction/ supernumeraries
- Habits e.g. thumb sucking
- Shape of the dental arches
- Tooth size asymmetry



FIRST ORDER

Abnormal molar rotations

- Result of early loss of deciduous molars
 - Mesial migration, forward tipping and rotation
- Space loss
- Ectopic mesial eruption of molar
- Mesio-palatal maxillary molar rotation will result in a more class 2 molar relationship on that side.

SECOND ORDER

Molar tipping

- Incorrect axial inclinations of the molars -Early loss of deciduous teeth

-Ectopic eruption

-Loss of space

- The mesial tipping results in a more class 2 molar relationship on that side

THIRD ORDER

- E.g. Dental crossbite due to abnormal axial inclination.

Centre-line discrepancy:

- Upper correct & lower incorrect
- Upper incorrect & lower correct
- Both incorrect to same side
- Both incorrect to opposite sides-uncommon

Differentiate between a centre line discrepancy and asymmetric arch crowding:

- Maxillary dental midline is situated in the middle of the Mouth (using the philtrum) in 70% population (Miller et al 1979)
- Maxillary and mandibular midlines coincide only in 25%population

Why aim for coincident CENTRE LINES ?

- well intercuspatated functional buccal occlusion
- Aesthetics

Actual CL discrepancy:

- Skeletal origin
- Dental origin
- Crowding
- Unilateral loss of teeth
- hypodontia
- Aberrant developmental position
- Supernumerary teeth
- Abnormalities of tooth form
- Carious or traumatized anterior teeth
- Habits
- Uncontrolled asymmetric space closure

Apparent CL discrepancy:

- e.g. mandibular displacement will suggest a CL discrepancy in maximum intercuspation which is absent in centric relation

Prevalence of Orthodontic Asymmetries (Sheats et al 1998):

- 62% Mandibular CL deviation from facial midline
- 46% L of coincidence of dental CL
- 39% Mx CL deviation from facial

- 22% Molar classification asymmetry
- 20% Mxocclusal asymmetry
- 18% Mdocclusal asymmetry
- 6% Facial asymmetry
- 4% Chin deviation
- 3% Nose deviation

Dental asymmetry mechanics:

Intra-arch mechanics

- Asymmetric extractions
- Continuous mechanics – undesirable side effects consider sectional mechanics for the initial phase
- Push pull mechanics
- Lacebacks on the canines
- Sliding teeth along the archwire
- Unilateral closing loops
- Rotations- trans palatal arch
- Implant anchorage

Inter-arch mechanics

- Intermaxillary traction
- Anterior diagonal elastics-ntw-undesirable side effects
- Headgear to supplement intra arch corrections
- Asymmetric headgear?-delivers a unilateral distal force but a net lateral force is also produced at the inner bow creating a lingual crossbite on the side that receives the larger distal force
- Correct asymmetry in the buccal occlusion early so symmetric mechanics can then be used.
- Asymmetric space closure mechanics

Hemifacialmicrosomia

- Type and timing of Treatment depends on severity, philosophy & protocols of interdisciplinary team.
- Variable in its expression-Spectrum mild to severe-Classifications
- Hard and soft tissues elements are missing.
- Growth potential is deficient
- Deficient growth on the affected side
- Primarily affects the mandible
- Maxilla is affected secondarily as deficient vertical growth of the mandible leads to distortion of the alveolar process.

Treatment goals

-Optimize facial growth

-Minimize secondary asymmetric development of the maxilla and canting of the occlusal plane.

Treatment

- Mild cases- asymmetric functional appliance- conservative approach, defer surgery

- Severe cases

Phase 1 surgery Tissue augmentation (5-8 years)

Phase 2 surgery Jaw relationships

Phase 3 surgery Modification of contour of skeleton & soft tissues

EARLY SURGERY (during growth)

- Distraction osteogenesis.-useful when hypo plastic ramus and condyle are present but extensive lengthening is required
- Costo-chondral bone graft.

-length to the ramus or

- Construct condyle ramus unit

The chin should be re-positioned in the centre of the face during this procedure, some grafts show over-growth.

LATE SURGERY (after the active growth period) The late procedure consists of either

-a distraction with a surgical intervention

-a classical osteotomy (i.e. bimax surgery with canting the maxilla in combination with advancement of the mandible and lengthening the ramus)

Timing of other important surgical interventions, such as the correction of the ear and soft tissues also depend on the severity of the malformation.

Asymmetric mandibular deficiency secondary early condylar fracture

- Proffit 1980 –previous fracture of condyle

5-10% of all severe asymmetry cases at UNC

- Most condylar fractures undiagnosed
- Proffit estimates in 1980

-75% children with early condylar fractures have no growth deficits-complete regeneration of the condyle essentially complete recovery. Better regeneration occurs in actively growing patients under the age of 12

-25% will have some growth deficit on the affected side soft tissue scarring restricts translation- functional ankylosis - restricts normal growth,& as normal facial growth continues the md may deviate towards the affected side or in some cases compensatory overgrowth of the fracture site may occur producing an asymmetry with the md deviating away from the affected side)

Maxilla affected secondarily/ distortion of the alveolar process.

TREATMENT mandibular deficiency secondary to condylar fracture

Greater the limitation of movement coupled with active growth the more rapid and severe the asymmetry

- PRE PUBERTAL CHILDREN a major cause of severe asymmetry. If the mandible moves enough to translate, it can grow -treat with Hybrid functional appliances.
- Early joint surgery- If no translation is possible - followed by hybrid functional appliance treatment to guide growth.
- ADOLESCENT-Functional appliance until growth completes to limit asymmetry/ cant.
- +/-later corrective surgery.

Hybrid Functional appliances

- Conservative approach-mild cases may attempt before surgery
- mild HFM
- History condylar fracture
- Depends on patient's growth potential.
- Md growth can only occur if translation of the condyles is possible. Both condyles must be able to translate.
- A child must be able to open about 20mm before chance of success with a functional appliance.
- Continue only if asymmetry is improving or stable
- Progressive asymmetry- Early surgery

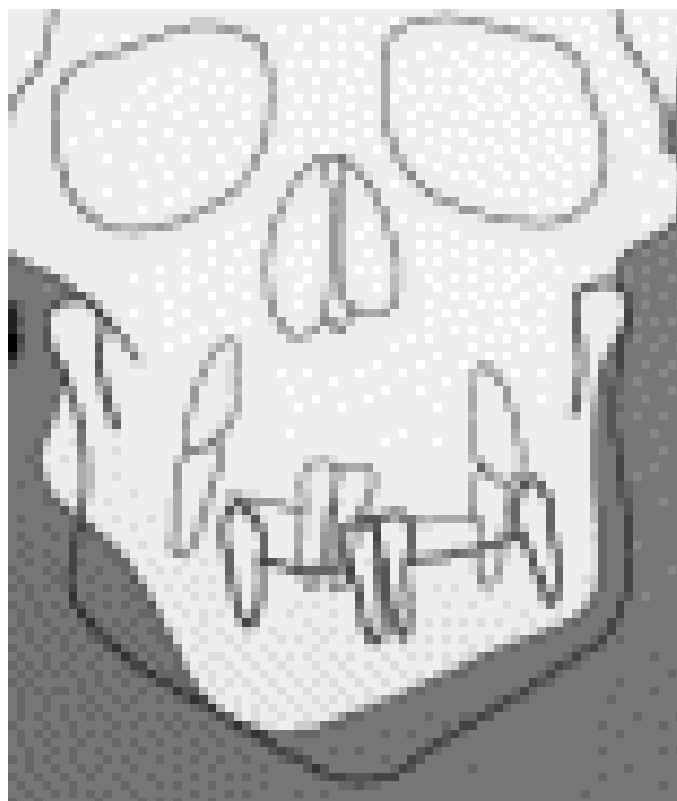
Construction bite

- Bring Mandible forward to asymmetric position vertically and transversely
- Wax soft on unaffected side and hard on affected side to open vertically more torque the ramus downward on the affected side.

Design Hybrid functional appliance

- Bite block on the normal side impede further vertical development, eruption
- Lingual pad to posture md to normal side
- On the affected side buccal (expansion) and lingual shields to prevent the tongue getting in between the teeth where vertical development is desired.

Asymmetry caused by unilateral hypoplasia-Distraction osteogenesis/orthodontic management



Because of the short vertical mandibular ramus, the chin deviates towards the affected side and the plane of occlusion in the maxilla becomes oblique in compensation.

This worsens as growth continues.

Goals of distraction

- Lengthening the hypoplastic ascending mandibular ramus
- correct the oblique plane of occlusion by creating a posterior vertical open bite on the affected side

Mandibular plane is lowered on the distracted side- Untreated maxillary upward cant-Prevent eruption of the md teeth - maintain open bite e.g. with unilateral posterior bite plate Adjust over several months to allow the eruption of the maxillary teeth down to the level of the md occlusal plane.

- Bring the chin to the midline to restore facial symmetry (overcorrection is often advised, but the developing opposite cross bite is the limiting factor. May correct with Mx expansion, but worsens crossbite on distracted side so counter with cross elastics .Lingual arch, to prevent molar inclination changes
- Questions remain unanswered. Mommaerts and Nagy
- the ideal age for treatment: mixed, permanent dentition?
- the influence on growth?
- the amount of overcorrection that is needed,
- the creation of the posterior vertical open bite?
- long-term stability?
- TIMING

Hemimandibular- hyperplasia/ hypertrophy/ elongation

MANAGEMENT-Is it progressing or has it ceased?

Can occur before or during the adolescent growth spurt but usually becomes apparent after the pubertal peak velocity of growth when one side of the mandible continues to grow after the other has all but stopped

- Excessive growth tends to be self-limiting, it may continue until a severe deformity has been created, especially if it starts prior to adolescence.
- DIAGNOSIS
- Early diagnosis – prevent secondary deformities
- In acute early stage bite is typically open on the affected site- eruption can't keep up with jaw growth.
- Long-term cases-teeth occlude but the frontal OP is canted.
- TESTS
- Is it progressing or has it ceased Scintigraphy to determine if asymmetric growth still occurring
- If asymmetric growth STOPS and the condition stabilizes better to delay surgery until the patient is a young adult and to correct the asymmetry without involving the TMJ
- If the asymmetry is already severe enough to cause a problem and is becoming PROGRESSIVELY WORSE there is no option even in young patients but to remove the growth site at the head of the affected condyle.(follow with a hybrid functional appliance to correct occlusion
- SURGICAL STRATEGY DEPENDS ON GROWTH ACTIVITY
- Condylar surgery to stop growth

Excision bone head condyle/ recontouring Remove condyle and condylar process & reconstruct area with costochondral junction transplant , or a free graft Plus BSSO on unaffected side to correct asymmetry of mandible Obwegeser classification 1986

HEMIMANDIBULAR ELONGATION

- elongation condyle or ramus in the vertical plane
- Or elongation of the mandibular body in the horizontal plane.
- Combinations of the V & H are also possible. characterized by excessive growth along normal growth axes.

Mandibular body or horizontal elongation

- mandibular midline deviating to the opposite side to the deformity
- a unilateral posterior crossbite on the opposite side from the elongation
- usually exhibits flattening of the gonial angle on the affected side,
- the mandibular borders and occlusal planes will superimpose on a centric relation cephalometric radiograph because there is no vertical component to the asymmetry
- mandibular elongation tends to stop when body or facial growth stops as it follows more of a somatic growth curve, variation of normal growth. Condyle or vertical ramus elongation
- compare condylar shape and morphology Compare differences between R & L condylar necks, sigmoid
- Growth will follow a normal pattern, like isolated mandibular body elongation, but will exhibit a vertical component, like hyperplasia.
- Orthognathics can be initiated when maturation is complete,

Hemimandubilar hyperplasia/ hypertrophy

- recognized by half of the entire mandible being enlarged. Overgrowth/ increase in bulk of bone
- Typically open bite on affected side early stage
- lower border, OPs don't superimpose, midline "notching" on the DPT
- Bowing md border & increased distances from the tooth apices to the lower border md when compared to the normal side.
- midline usually deviates to the same side as the deformity
- normal or more acute gonial angle due to excessive vertical development.
- vertical differences in both planes
- Hyperplasia type tends to grow longernotches, and vertical rami.
- md borders & OPs wont superimpose exhibiting "latent" growth

Skeletal scintigraphy- 99mTc Bone scan

- Dynamic means of growth analysis that depends on the differential uptake of a radiopharmaceutical into metabolically active bone.
- Identify "hotspots" and whether there is excessive bony remodeling in certain areas.
- Injected with radiopharmaceutical .the pharmaceutical component locates the area of interest Radioactive component emits Gamma radiation detected using gamma camera
- Direct way to determine if asymmetric growth is occurring.
- More uptake of the isotope on the affected side than on the unaffected one indicates active asymmetric growth.

- False positives are rare
- Clinical observation of continuing growth may indicate surgery to remove the affected condyle even though repeated bone scans do not demonstrate continued isotope uptake. False negative occur- because growth is not continuous if negative consider, repeat in 6/12.
- Progressive asymmetry
- Wait 6/12 compare records
- Scan to see burn out
- Involve Patient in the risk benefit
- Not to be requested lightly

Skeletal asymmetries

- more easily recognized in older individuals because progressive asymmetries become more fully expressed and obvious with continued growth and maturation.
- Orthodontists, however, see young patients, often starting treatment in the mixed dentition or sooner, which may be too early to clearly recognize the signs of a developing asymmetry.
- The tendency is to compensate mechanically during early treatment because the asymmetry can be subtle or mild and the differences in growth rate small.
- The mandible is the dominant contributor to dentofacial asymmetry. Forms skeletal support for the soft tissue of the lower face
- Maxilla provides minimal soft tissue support
- Maxilla plays a small part in asymmetry
- Most maxillary asymmetry is secondary to asymmetric mandibular growth

Dentoalveolar compensation.g. Patient with asymmetric mandibular prognathism

Typically Mandibular incisors will be retroclined + tipped towards the more CIII side

Maxillary incisors will be flared typically + tipped away from the CIII side

Recognize the early signs

- asymmetric canine overjet,
- different torque requirements between the right and left buccal segments,
- need for asymmetric mechanics,
- development of a unilateral posterior openbite
- and posterior arch length differences resulting in “stacking up” of second and third molars on the shorter side.

Do we need to treat?

- Is it progressive?
- Associated with functional asymmetries worsening underlying skeletal disproportion?
- What is the cause of the deformity?
- Magnitude of deformity?

Asymmetry- Orthognathic Surgery

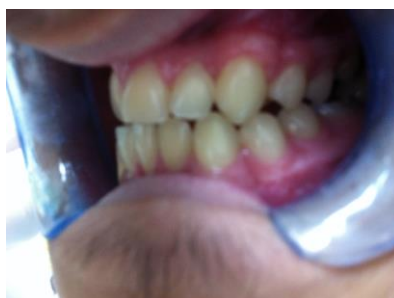
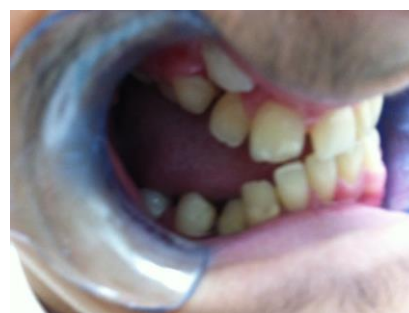Pre- surgical orthodontics

- Remove dental compensation for the skeletal deformity in 3 planes. Ideally position the teeth over the basal bone.
- Transverse decompensation

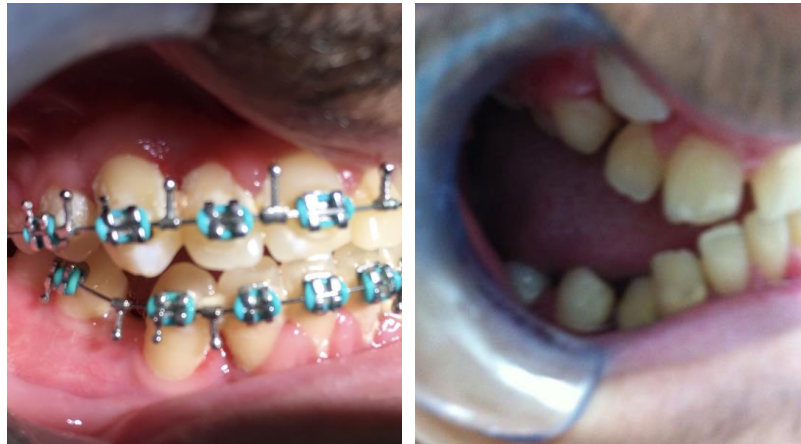-asymmetric extraction so the midline shifts in the desired direction as the extraction space is closed

-asymmetric elastics, usually anterior diagonal elastics with space midline can be shifted several mm, no space only small changes possible

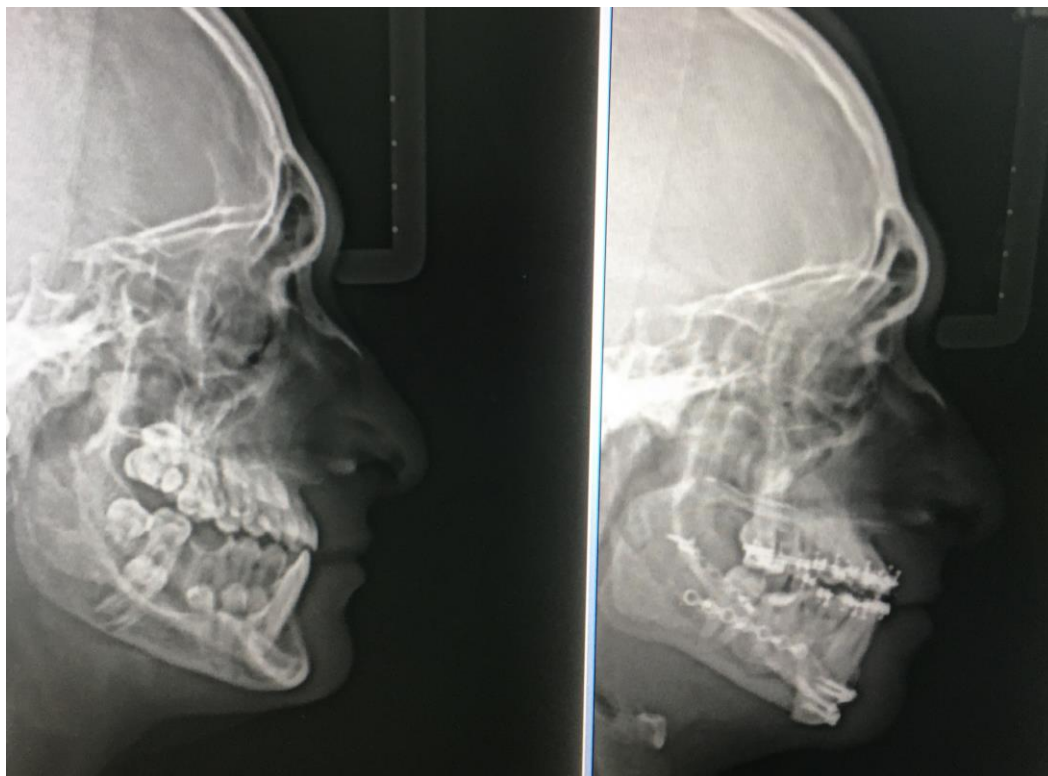- Segmental arch mechanics may be indicated with segmental osteotomies.
- Better to decompensate the dentition pre- surgically to the extent that is possible. If dental compensations cannot be removed by the pso the surgical approach must be modified to take this into account.
- ORTHOGNATHIC SURGERY
- Vertically asymmetric Maxilla the greater stability of superior versus inferior repositioning
- Correction of maxillary cant will lead to problems with mandibular fixation: consider VSSO
- Consider VSSO when reducing ramus height unilaterally
- Severe asymmetry Mandible ramus-Consider extra oral approach- better access and visualization. Modification of the osteotomy technique
- Moderate asymmetries BSSO
- Asymmetric repositioning mandible often makes it necessary to place bone grafts in defects in the ramus osteotomy sites.
- Correction of 3d asymmetry makes alignment of jaw segments unpredictable..RIF may need to be plus IMF for 4-6/52 .Post surgical orthodontics.
- Asymmetric elastics are likely to be needed initially in patients who have had surgical correction of asymmetry.
- Especially true if the Md has been brought to the midline by moving one side more than the other after a BSSO
- Box elastics with a Class II component on one side & a Class III component on the other in conjunction with the initial arch wires and then to use triangular elastics as required to maintain symmetry while the patient learns to use their jaws in their new position.



Pre-surgical



post -surgical



post-surgical lateral ceph

Functional asymmetry- Identify Mandibular displacements

- Mandibular displacement

Result of the mandible being deflected laterally or AP if occlusal interferences prevent it achieving intercuspation in centric relation. (Caused by e.g. constricted maxillary arch/local factors e.g.malpositioned tooth.

The abnormal initial tooth contact in centric relation results in the subsequent mandibular displacement in maximum intercuspation.)

A mandibular displacement disguises true skeletal relationship- e.g.mandibular displacement will suggest a transverse mandibular asymmetry that is absent in centric relation

-In a patient with a true dental or skeletal asymmetry the mandibular displacement may be in the same or opposite direction as the dental/skeletal discrepancy & may accentuate or mask the asymmetry.

“Occlusal splint”-

-Clinical exam may not detect a suspected displacement

- Diagnostic aid in determining centric relation if it is difficult to obtain and properly evaluate the presence and extent of the displacement
- eliminating habitual posturing & occlusal interferences

Functional asymmetry

Unilateral anteriorly displaced disc without reduction

On Opening

The mandible may shift to the affected side because the displaced disc may not allow the condyle to translate as far forward as on the normal side

On Closure

The mandibular midline shifts back to its normal position in centric occlusion

Functional asymmetry-management

- Minor deviations- minor occlusal adjustments(systematic review Cochrane library, Harrison and Ashby 1998 <http://www.cochrane-oral.man.ac.uk>, Bishara 1996)
- A Crossbite associated with a displacement is a functional indication for orthodontic treatment. Treat as early as possible as may predispose to TMD in a susceptible individual.
- As a result of skeletal asymmetry –
- Orthodontic/orthopaedic/ surgical maxillary expansion (S.A.R.P.E.)
- Orthognathic surgery

Muscular asymmetry

- Cerebral Palsy
- Hemifacial atrophy (rare)
- Torticollis
- Masseter hypertrophy
- Tumours

Asymmetry - Summary

- Thoroughly evaluate the initial history and diagnostic records
- Is the asymmetry a result of skeletal asymmetry, asymmetry within the dental arches, or a discrepancy between centric relation & maximum intercuspation or a combination?
- Always check for a functional component to the malocclusion and take the appropriate records in centric relation.
- Asymmetry in the buccolingual relationships e.g. unilateral posterior crossbite should be carefully diagnosed to determine if it is skeletal, dental or functional.

- Recognize the early signs of progressive asymmetry
- Understand the dento-alveolar compensations associated with the various types of asymmetries.
- Take progress records and re-evaluate if there is reason to suspect that the patient has an underlying progressive asymmetry.

REFERENCES

- [1] Bishara S.E. et al 1984 Dental and facial asymmetries a review. AO 64;89-98
- [2] Holmes et al The correction of Dental Centre Line Discrepancies Using an edgewise appliance.JO 1988
- [3] Seminars in Orthodontics – Asymmetry edition 1998
- [4] Shroff B and Siegel SM Treatment of patients with asymmetric mechanics. SeminOrthod 1998;4;165-179 Rebellato-Asymmetric extractions used in the treatment of patients with asymmetries. Seminars in Orthodontics1998
- [5] Severt T.R., Profit W.R. The prevalence of facial asymmetry in the dentofacial deformities population at the University of North Carolina, Int J Adult OrthodOrthognathicSurg 12;171-176,1997
- [6] C. Moulin-Romsée, A. Verdonck, J. Schoenaers and C. Carels Journal of Orthodontics, Vol. 31, No. 3, 190-200, September 2004
- [7] Diagnosis and treatment planning of patients with asymmetries. Burstone C.J.
- [8] Legan H.L. Surgical correction of patients with asymmetries. SeminOrthod 1998;4;189-198
- [9] Lundstrom A. Some asymmetries of the dental arches, jaws, and skull and their etiological significance. Am J Orthod 1961;47;81-106
- [10] Proffit W.R., Vig KWL, Turvey TA. Early fracture of the mandibular condyles: frequently an unsuspected cause of growth disturbances.Am J Orthodontics 1980,78;1-24